Aerosol Inoculation of Opossum (*Didelphis virginiana)* and Lateral transmission of *Mycobacterium bovis*

Karla Mesterhazy, Scott Fitzgerald, James Sikaskie, Konstantine Lyanschenko, John Kaneene, Steve Church, Dale Berry

Department of
Pathobiology and Diagnostic Investigation
Michigan State University College of Veterinary Medicine

Overview

- *M. bovis* in Opossum
- Specific Aim
- Hypothesis
- Materials & Methods
- Results
  - Necropsy
  - Serologic
- Conclusions

M. bovis in Opossums

- Mycobacterium Tuberculosis Complex
  - M. bovis
  - Wildlife, domestic animals and humans
  - Identifying reservoirs and routes of transmission essential to eradication
- United States
  - Sporadic
  - Endemic focus in cevids in northern Michigan
- New Zealand
  - Brushtail possum
- United States opossum
  - Known host in Michigan
  - Experimentally Infected
    - Oral
    - IM
    - Aerosol

Mycobacterium bovis Pathogenesis

AFB



Inhaled, Ingested, or

Direct Contact →

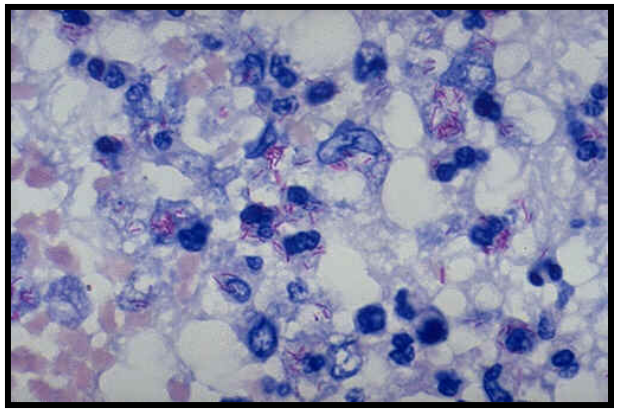

Intracelluar AFB

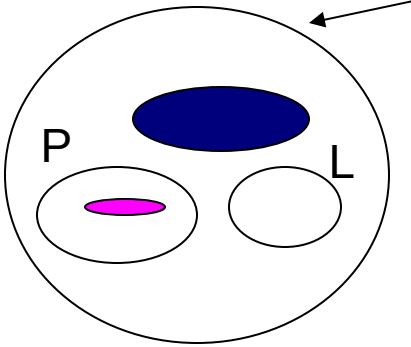

Phagosome arrest

AFB multiply →

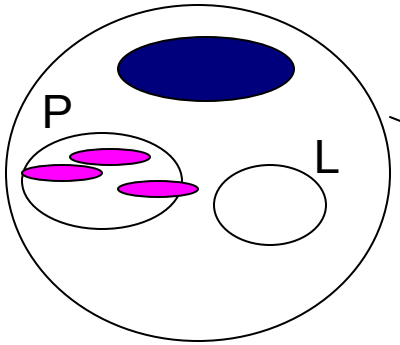

Local Tissue Rxn

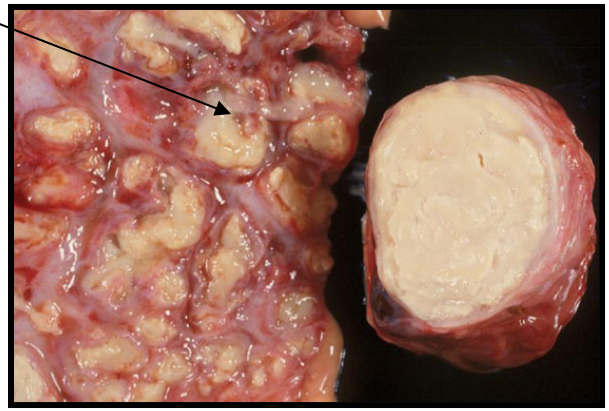

Specific Aim

Determine if wild mammals

other then deer

are shedding *M. bovis* and

contributing to spread of disease by looking at interspecies spread

Hypothesis

Following aerosol inoculation of wild opossums, significant lateral transmission by direct contact will occur between additional non-inoculated opossums.

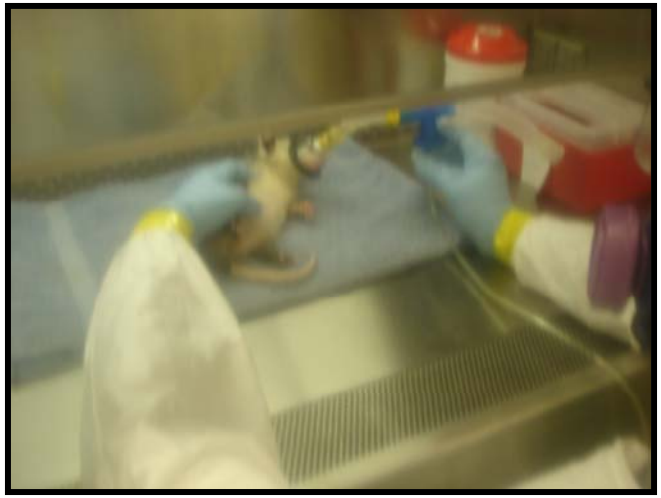

Materials & Methods

Wild Caught Female Opossum

- Babies (12 total: 7 F, 4 M +1M)

Materials & Methods

- Animals
  - 4 Inoculated, 4 Exposed, 4 Controls
- Weigh-every 2 weeks
- Inoculated
  - Aerosol ~10^6 CFU,10 mins
- Exposed-Cohabitation after 1 week
  - Cohabitate for 1.5 months
- Necropsy
  - Day 84 post-inoculation/exposure

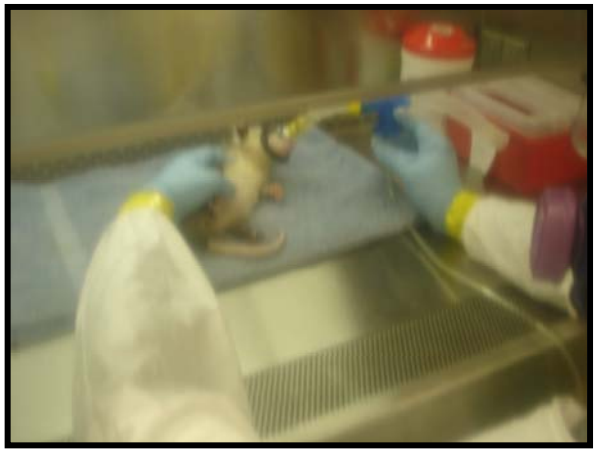

Materials & Methods

Organ Weights (grams)

a. Lungs
b. Liver
c. Kidneys
d. Spleen

Histopathology and Acid-Fast Staining (fix in 10% neutral buffered formalin, stain with hematoxylin & eosin (H&E), and Ziehl-Neelsen (acid fast)

e. Brain
f. Eye
g. Nasal turbinates
h. Trachea
i. Lungs
j. Heart
k. Liver
l. Kidney
m. Spleen
n. Stomach
o. Pancreas
p. Gonad
q. Adrenal gland
r. Small Intestine
s. Large Intestine
t. Lymph nodes-cranial & tonsil, thoracic, and abdominal
u. Urinary Bladder
v. Skeletal Muscle
w. Pinea

Culture for *Mycobacterium bovis* (send to MDCH for processing)

x. Group A
    i. Lymph nodes- cranial & tonsil
y. Group B
    i. Lymph nodes- thoracic
    ii. Lungs
z. Group C
    i. Liver
    ii. Kidney
    iii. Spleen
    iv. Lymph nodes- abdominal
aa. Group D
    i. Small Intestine
    ii. Large Intestine

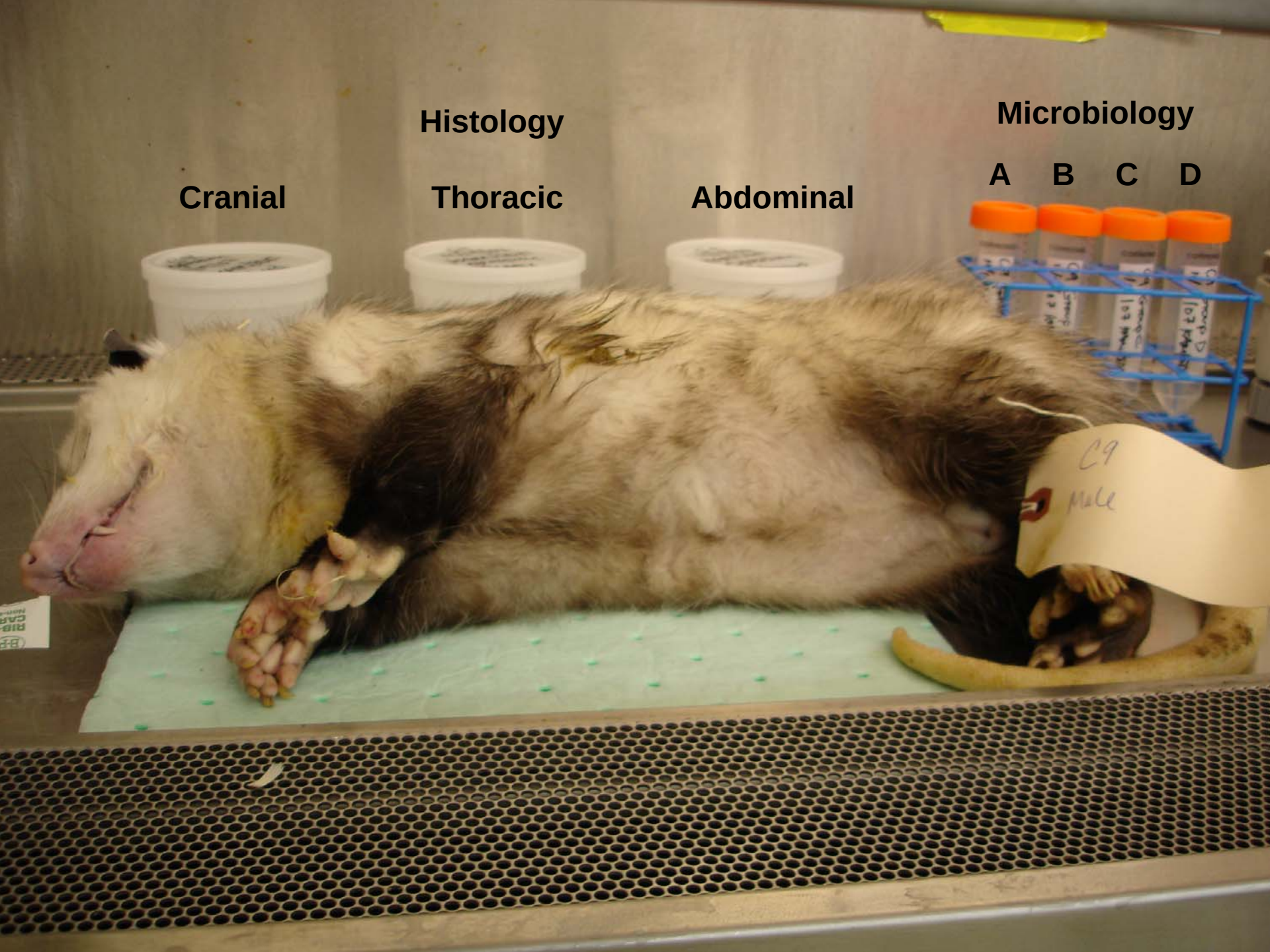
Histology
Microbiology
A B C D
Cranial
Thoracic
Abdominal
C9
Male

Results

- Gross Examination
  - Inoculated
    - Marked, multifocal, granulomatous pneumonia
  - Exposed & Controls
    - No gross lesions

Results

- Histology
  - Inoculated
    - Marked, multifocal, granulomatous pneumonia
  - Exposed & Controls
    - No gross lesions

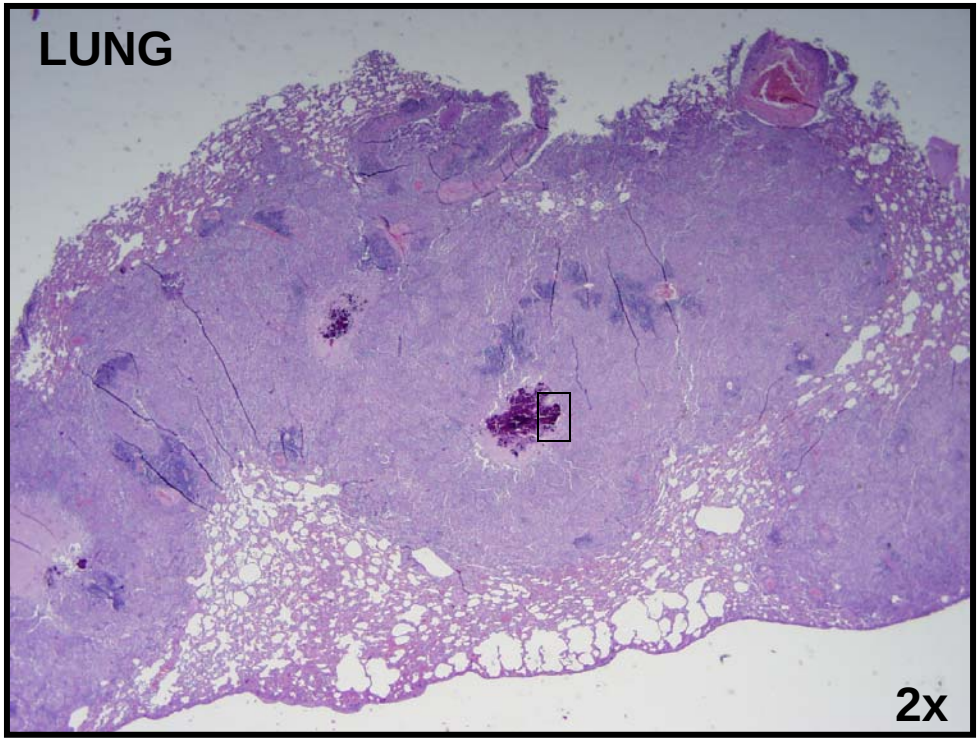

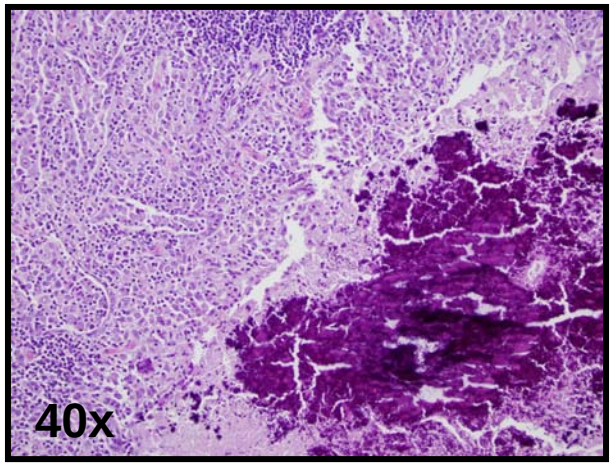

Results

- Average Weight Gain
  - Inoculated (425g)
  - Exposed (385g)
  - Controls (502g)

Results

Weight: Average % Total Body

- *Inoculated*
  - % Lung
    - 0.0975
  - % Liver
    - 0.53
  - % Kidney
    - 0.0675
  - % Spleen
    - 0.03
- *Exposed*
  - % Lung
    - 0.0525
  - % Liver
    - 0.3675
  - % Kidney
    - 0.05
  - % Spleen
    - 0.025
- *Controls*
  - % Lung
    - 0.05
  - % Liver
    - 0.365
  - % Kidney
    - 0.0475
  - % Spleen
    - 0.02

Results

Weight: Average % Total Body

- *Inoculated*
  - % Lung
    - 0.0975
  - % Liver
    - 0.53
  - % Kidney
    - 0.0675
  - % Spleen
    - 0.03
- *Exposed*
  - % Lung
    - 0.0525
  - % Liver
    - 0.3675
  - % Kidney
    - 0.05
  - % Spleen
    - 0.025
- *Controls*
  - % Lung
    - 0.05
  - % Liver
    - 0.365
  - % Kidney
    - 0.0475
  - % Spleen
    - 0.02

Results

- Culture
  - Upper Resp.
    - None
  - Lower Resp.
    - All Inoculated
  - Systemic
    - Half Inoculated
  - Alimentary
    - None

Results

- Rapid Test (ESAT-6, CFP10, Acr1, MPB83)
  - Inoculated
    - Positive Reaction
  - Exposed
    - No Reaction
  - Controls
    - No Reaction

Rapid Test

Inoculated

Exposed

Controls



Conclusion

We conclude that there is no significant lateral transmission after aerosol inoculation of *M. bovis* and 45 days co-habitation between wild opossum; therefore there is little risk for natural spread of the disease between individuals of this species.

Acknowledgements

- Michigan State University
  - Scott Fitzgerald
  - Steve Bolin
  - John Kaneene
  - John Kruger
  - James Sikarskie
  - Necropsy & Histology Technicians
- Chembio Diagnostic Systems Inc.
  - Konstantin Lyashchenko
- MDA
- MDCH
  - Dale Berry
  - Steve Church
  - Lab Technicians

References

- Bruning-Fann, C., S. Schmitt, S. Fitzgerald, J. Payeur, D. Whipple, T. Cooley, T. Carson, and P. Friedrick. *Mycobacterium bovis* in Coyotes from Michigan. 1998. Journal of Wildlife Diseases. 34(3) pp 632-636.
- Bruning-Fann, C., S. Schmitt, S. Fitzgerald, J. Fierke, P. Friedrick, J. Kaneene, K. Clarke, K. Butler, J. Payeur, D. Whipple, T. Cooley, J. Miller, and D. Muzo. Bovine Tuberculosis in Free-Ranging Carnivores from Michigan. 2001. Journal of Wildlife Diseases. 37(1) pp 58-64.
- Diegel, K., S. Fitzgerald, D. Berry, S. Church, W. Reed, J. Sikarskie, and J. Kaneene. Experimental Inoculation of North American Opossums (*Didelphis virginiana*) with *Mycobacterium bovis*. 2002. Journal of Wildlife Diseases. 38(2). Pp 275-281.
- Fitzgerald, S., L. Zwick, K. Diegel, D. Berry, S. Church, J. Sikarskie, J. Kaneene, and W. Reed. 2003. Experimental Aerosol Inoculation of *Mycobacterium bovis* in North American Opossums *(Didelphis virginiana*). Journal of Wildlife Diseases. 39(2). Pp 418-423.
- Thoen, C., J. Steele, and M. Gilsdorf. 2006. *Mycobacterium bovis* Infections in Animals and Humans. 2nd ed. Blackwell Publishing. Ames, IA.
- Images
  - http://www.s-secretarial.co.uk/Weighing-Alternatives%20Icon.jpg
  - http://www.johnes.org/general/diagnosis.html
  - http://www.targetpest.co.nz/images/cow_possum_000.jpg
  - http://farm3.static.flickr.com/2296/2349714332_932be43cec.jpg?v=0
  - http://www.hiltonpond.org/images/OpossumVirginia01.jpg

Questions